

Tumors Of The Brain Stem, Cerebellum, and Fourth Ventricle

ROGER J. PACKER, HENRY S. FRIEDMAN,
LARRY E. KUN, AND GREGORY N. FULLER

The posterior fossa is a small region of brain cradled on all sides by bone and limited above by the tentorium. The brain stem, cerebellum, and fourth ventricle occupy this region of brain. Expansion of a mass in this infratentorial area occurs at the expense of the normal structures in the region and may result in brain stem or cerebellar dysfunction, often associated with blockage of the fourth ventricle and hydrocephalus. Although many different tumor types may arise in the posterior fossa and affect the brain stem, cerebellum, and fourth ventricle, the majority are either medulloblastomas, cerebellar astrocytomas (rarely, higher grade cerebellar glial tumors), brain stem gliomas, or ependymomas. Other tumor types, which may arise less frequently, include choroid plexus papillomas, germ cell tumors, and dermoid lesions. Because tumors do not respect discrete compartmental landmarks, those that arise in the thalamus or suprasellar region can extend inferiorly into the posterior fossa. Similarly, lesions that arise from the spinal cord can extend up into the medullary area and cause symptoms of brain stem dysfunction.

Fewer than 5% of all adult tumors originate in the posterior fossa, whereas approximately 50% of primary central nervous system (CNS) tumors occurring in patients younger than 15 years of age arise in the fourth ventricular region. For unclear reasons, lower grade lesions in children are more frequently found

in the posterior fossa than those in adults. Ependymomas, which are more frequent in a supratentorial region in adulthood, are more frequently found in the posterior fossa in childhood.

With the modern neuroimaging techniques, which have replaced previously used tests such as pneumoencephalography and angiography, these tumors can now be diagnosed at earlier stages of disease. Computed tomography (CT) delineates the presence of tumor in greater than 95% of patients with posterior fossa tumors, but, due to bone artifact obfuscation, this technique has limited applicability. For lesions that arise deep within the posterior fossa, especially those at the cervicomedullary junction, and for lesions that infiltrate the brain stem, magnetic resonance imaging (MRI) has become the procedure of choice. The beauty of MRI is that it allows scanning in all planes without reformatting, which makes it easier to anatomically define a lesion in the brain stem or deep in the cerebellum. The extent of the infiltrating component of posterior fossa tumors, especially those that infiltrate the brain stem, are visualized considerably better with MRI than with CT.

The clinical presentation associated with posterior fossa tumors is essentially similar in adults and children. In general, the briefer the history, the more likely the tumor is to be growing rapidly and arising in the axial midline of the posterior fossa, obstruct-

ing cerebrospinal fluid (CSF) flow. Late in the course of illness, symptoms usually include increased intracranial pressure, focal neurologic deficits secondary to compromise of brain stem or cerebellar tissue, and meningeal irritation, whereas early in the course of illness nonspecific complaints of vague, intermittent headache, fatigue, and personality change may predominate. The clinical triad of increased intracranial pressure—headache, vomiting, and blurred or double vision—is the hallmark of an infratentorial tumor. Although a classic headache of increased intracranial pressure is common late in the disease, early on the headache may be far less specific. Similarly, vomiting, which occurs in the morning and is associated with relief of head pain, is a footprint of posterior fossa tumors that have obstructed the fourth ventricle. Less frequently, vomiting may occur secondary to tumors that invade or compress the floor of the fourth ventricle, especially in the medullary area. The vomiting pattern from such lesions is usually more constant during the day and is associated with persistent nausea, anorexia, and significant weight loss.

Cerebellar deficits occur in most patients with posterior fossa tumors. In midline lesions, compromise of the anterior and posterior lobes of the cerebellum causes truncal and gait ataxia manifested by unsteadiness when sitting and a staggering gait. Limb ataxia occurs more frequently in lesions that involve the lateral cerebellar hemispheres, most commonly cerebellar astrocytomas. However, brain stem lesions that infiltrate the cerebellar peduncles will frequently cause cerebellar symptomatology.

Other focal neurologic deficits may occur in patients with posterior symptoms. Ocular motor deficits are relatively frequent and tend to be of localizing value, except for a sixth nerve palsy, which may be present secondary to diffuse increased intracranial pressure. Epileptic seizures rarely occur in children or adults with subtentorial tumors except in patients with infiltrating masses that extend into the subcortical areas and in patients with lesions that have disseminated into the nervous system. Alterations in consciousness may occur, but tend to be a late finding. Acute hemorrhage into a posterior fossa tumor may result in acute coma.

Infants and young children with posterior fossa tumors are notoriously difficult to diagnose, although they may have increasing head circumference due to their open sutures and fontanelles.

SPECIFIC TUMORS

Medulloblastoma

Medulloblastomas are common tumors of childhood in the posterior fossa. They typically arise in the vermis but can arise in the cerebellar hemisphere (Fig. 6–1). Medulloblastomas are classic “small round blue cell” tumors in which neoplastic cells may exhibit various organizational patterns, including unstructured sheets, nests, and cords. Four named morphologic variants are recognized by the current WHO classification: classic medulloblastoma, desmoplastic medulloblastoma, medulloblastoma with extensive nodularity and advanced neuronal differentiation, and large cell medulloblastoma. In addition, there are two very rare related neoplasms: melanotic medulloblastoma and medulloblastoma (medulloblastoma with skeletal muscle differentiation). All medulloblastoma variants are malignant neoplasms in which mitotic figures are typically numerous and necrosis is often present. Rapid growth with secondary involvement of the fourth ventricle and seeding via CSF pathways is common.

The desmoplastic medulloblastoma, a histologic variant of the medulloblastoma, received its name from the abundance of connective tissue present, which can be seen particularly well with reticulin or Masson trichrome stains. The distinctive appearance of this tumor derives from the contrast of background with scattered circumscribed areas that lack a connective tissue stroma, so-called “pale islands” (Fig. 6–2). Such foci often exhibit glial or neuronal differentiation demonstrated by immunopositivity for glial fibrillary acidic protein or synaptophysin, respectively. The prognostic significance of the desmoplastic variant and glial/neuronal differentiation is not yet known.

In addition to medulloblastoma, another entity in the differential diagnosis of a malignant neoplasm arising in the cerebellum of a young child is atypical teratoid/rhabdoid tumor (ATRT). These neoplasms can resemble medulloblastoma, particularly the large cell medulloblastoma variant. In general ATRTs are more heterogeneous and pleomorphic than medulloblastomas and their immunophenotypic profile is distinctive: All are immunopositive for vimentin, the vast majority (95%) are positive for epithelial membrane antigen (EMA), and a large percentage (60% to 75%) show positivity for smooth muscle antigen.

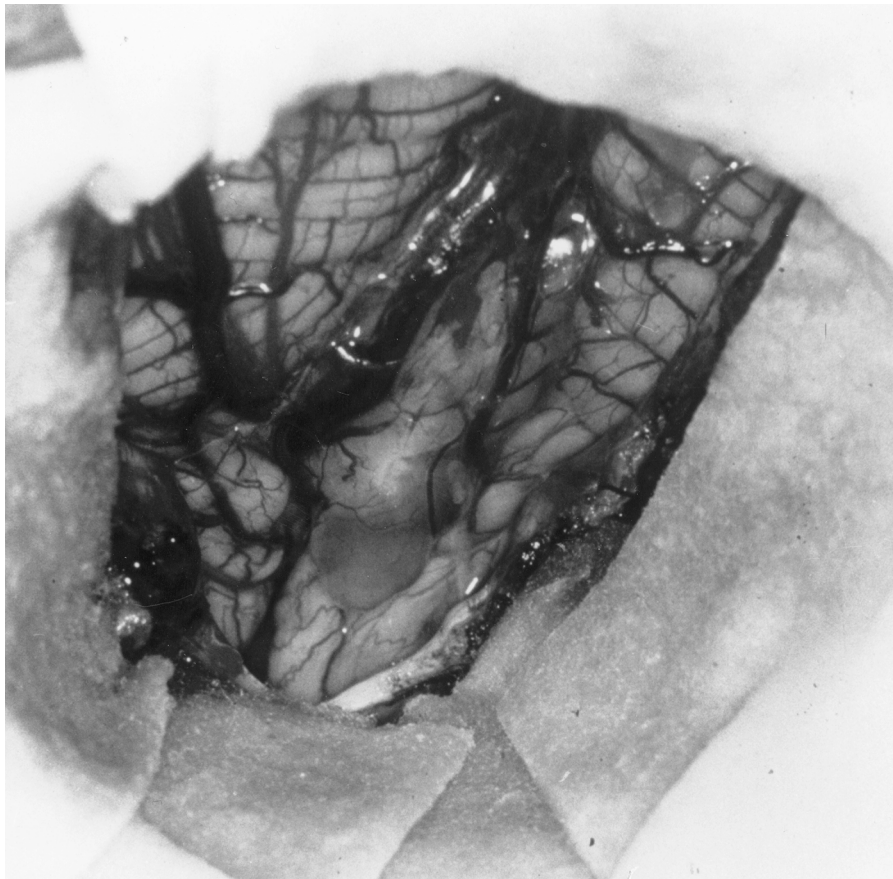


Figure 6-1. Medulloblastoma visible in vermis at time of surgery. Note herniation of cerebellar tonsils.

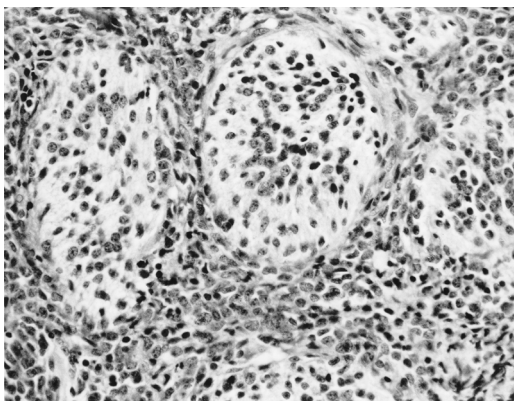


Figure 6-2. Desmoplastic medulloblastoma. Like all medulloblastomas, this variant is composed of small neoplastic cells with hyperchromatic nuclei and scant cytoplasm. In desmoplastic medulloblastomas, there is an abundant reticulin stroma throughout the tumor, except in scattered, roughly spherical, aggregates termed "pale islands," thus imparting a distinctive architectural pattern.

In addition to these markers, a wide range of other antigens may be expressed, including epithelial (keratins) and neural (GFAP, synaptophysin) markers (Kleihues and Cavenee, 2000). ATRTs are aggressive tumors with a tendency for widespread dissemination via cerebrospinal pathways.

Presentation

Patients with medulloblastoma typically present with vomiting, headache, and an ataxic gait (Cushing, 1930). Manifestations of obstruction of the fourth ventricular outlet include vomiting, headache, lethargy, and occasionally papilledema. Vomiting secondary to a medulloblastoma usually occurs when the child awakens in the morning and may precede resolution of complaints for the remainder of the day. Progressive awkwardness and clumsiness, with difficulty standing or walking alone, results from in-

Table 6–1. Staging of Patients with Medulloblastoma

	<i>Average Risk</i>	<i>Intermediate Risk</i>	<i>Poor Risk</i>
Age (years)	Older than 3 years of age	Older than 3 years of age; less than 3 years of age with increased TrkC	Younger than 3 years of age
Tumor resection	Total/near-total localized	? Partial	Biopsy and/or partial
Extent		? Disseminated with increased TrkC; ? brain stem involvement	Disseminated alone or with ? decreased TrkC

TrkC, type C tyrosine kinase neurotrophin receptor.

? Signifies possible but not conclusively proven to date.

involvement of cerebellar hemispheres. These findings may be more common in adults, as tumors in adults are somewhat more frequently lateral lesions arising in the cerebellopontine angle. Cranial nerve palsies, particularly of the sixth and seventh nerves, may also be seen. In some patients, medulloblastomas will hemorrhage and cause acute neurologic compromise, including coma.

Staging

Staging is one of the cornerstones of managing patients with medulloblastoma (Table 6–1). Approximately one-third of children with medulloblastoma will have disseminated disease at the time of diagnosis, and an even higher percentage of children younger than 2 years of age will manifest such dissemination. The rate of dissemination in adult patients is poorly characterized, but probably occurs in 10% to 20% of patients at diagnosis. As would be expected, disseminated disease carries a poorer prognosis than localized disease (Zeltzer et al., 1999).

Patients with medulloblastoma are staged with either pre- or postoperative MRI of the entire neuraxis, and CSF cytology is generally performed following surgery. Some patients have free-floating tumor cells present after surgery that disappear spontaneously. Positive CSF cytology on studies performed 2 to 3 weeks after surgery has been related with a poorer outcome. Lumbar CSF cytology is more sensitive for detecting free-floating tumor cells than ventricular fluid analysis (Gajjar et al., 1999).

Although, in the past, bone scans and bone marrow examinations were utilized to determine the extent of dissemination, their yield is quite low, and such investigations are now usually limited to those patients at highest risk, including children younger than 3 years of age or those with disseminated disease in the leptomeninges.

Based on staging studies and on the extent of surgical resection, most patients with medulloblastoma can be stratified into two major risk groups. The first includes patients with localized disease at the time of diagnosis and extensive (total or near-total) resections. Such patients are thought to have average-risk disease and constitute approximately 60% to 70% of patients (possibly more in adults) and have a 60% to 65% chance of 5 year progression-free survival (PFS) after treatment with craniospinal and local radiotherapy. Patients with disseminated disease or partially resected tumor have “poor-risk” disease. Patients with “poor-risk” disease have approximately a 40% likelihood of 5 year PFS after treatment with craniospinal and local radiotherapy. The presence of brain stem involvement at the time of diagnosis was initially thought to be of prognostic importance, but in more recent studies brain stem involvement at the time of diagnosis has not been shown to predict outcome (Zeltzer et al., 1999). Age is a powerful predictor of outcome, as younger patients (primarily those younger than 3 years of age at diagnosis) fare poorly. All these factors are affected by treatment, and in some studies the predictive significance of any one parameter or parameters may be abrogated by altering treatment (such as adding chemotherapy). More recently, determination of neurotrophin expression in medulloblastoma tissue has been found to be a strong predictive factor, as patients with higher expression of type C tyrosine kinase neurotrophin receptor (TrkC) have a better prognosis (Grotzer et al., 2000). The predictive interaction between extent of tumor at diagnosis, age, TrkC expression, and treatment is still being delineated.

Surgery

The aim of surgery for medulloblastoma is total removal. Because these tumors are malignant, adjuvant

tive therapy is necessary for their management (Deutsch, 1988; Jenkin et al., 1990; Levin et al., 1988; Rutka et al., 1990). The best results are obtained when the tumor is totally or almost totally removed with no evidence of metastatic deposit (Tomita and McLone, 1986; Zeltzer et al., 1999). Approximately 30% to 50% of children with medulloblastoma will require permanent ventriculoperitoneal shunting after surgery, although some surgeons believe that this need is lessened when patients are diagnosed early and have smaller tumors. Some patients have a transient need for CSF diversion before or immediately after surgery, which can be accomplished by external ventricular drainage. Some surgeons prefer to place a catheter between the third ventricle and cisterna magna at the time of craniectomy and tumor removal (Hoffman et al., 1976) as ventriculoperitoneal shunting is not without complications in this patient population. In addition to the potential for CSF infections, young children may require shunt modification to keep pace with growth, and sometimes their hydrocephalus is associated with extremely low pressure, making incorporation of a valve in the shunting path problematic and shunt revisions a likelihood.

Radiotherapy

The principles of radiotherapy are similar for medulloblastoma, ependymblastoma, and the putative undifferentiated primitive neuroectodermal tumor (PNET). These tumors classically spread through CSF pathways, suggesting that the role of craniospinal irradiation is to systematically encompass the entire subarachnoid space. Craniospinal irradiation is a technically demanding treatment requiring immobilization in the prone position for all patients except the very young. Therapy includes lateral craniocervical fields adjoined to posterior spinal fields to achieve homogeneous coverage of the neuraxis. Detailed attention to the subfrontal cribriform plate just above the eyes and the lower margin of the temporal fossa challenge the radiation oncologist in reproducibly ensuring appropriate treatment volume while avoiding direct irradiation of the eyes. In addition to craniospinal irradiation, a local posterior fossa boost is utilized to raise the dose to a higher level at the primary site.

The radiation dose for the posterior fossa is relatively well established in medulloblastoma based on the relative radiosensitivity of these tumors and the

clinical observation in local posterior fossa disease that tumor control is optimal following doses of 54 to 55 Gy (Silverman and Simpson, 1982; Fertil and Malaise, 1985; Hughes et al., 1988; Jenkin et al., 1990).

Several recent studies confirming long-term survival in more than 50% of patients with medulloblastoma utilized craniospinal irradiation doses of 35 to 40 Gy to the neuraxis (Bloom et al., 1990; Jenkin et al., 1990; Halberg et al., 1991). The suggestion that a reduced neuraxis dose can provide equivalent disease control with potentially less late morbidity in selected "average-risk" populations (grossly resected, localized disease of limited extent) has been tested by two North American pediatric cooperative groups. A study conducted by the Pediatric Oncology Group and the Childrens Cancer Group demonstrated a higher rate of leptomeningeal disease control following 23.4 Gy craniospinal irradiation compared with the standard 36 Gy dose (Deutsch et al., 1996). However, further analysis revealed less of a difference in long-term disease control between patients treated with reduced-dose radiotherapy and those treated with conventional-dose craniospinal radiotherapy (Thomas et al., 1995).

The relative radiosensitivity of medulloblastoma and the exquisite relationship between dose per fraction and neurotoxicity suggest that hyperfractionated irradiation may be useful in treating this tumor (van der Kogel, 1991); but, to date, such trials have not demonstrated added efficacy (Allen et al., 1996; Kun et al., 1990; Prados et al., 1994; Prados et al., 1999).

Chemotherapy

Medulloblastoma is one of the more chemosensitive brain tumors of the pediatric population (Friedman and Oakes, 1987; Friedman et al., 1992). Nevertheless, results of three large randomized studies evaluating adjuvant chemotherapy have shown only modest benefits of this modality confined to patients with advanced disease (Evans et al., 1990; Tait et al., 1990; Krischer et al., 1991). Disappointment with these results must be tempered by recognition that all three studies included inadequately staged patients and incorporated chemotherapeutic agents now known to possess dubious anti-medulloblastoma activity.

Data from extensive preclinical studies with a panel of human medulloblastoma cell lines and transplantable xenografts in athymic mice as well as a se-

ries of phase II trials have confirmed the activity of cisplatin, cyclophosphamide, and melphalan against medulloblastoma (Friedman and Oakes, 1987; Friedman et al., 1988, 1989). Furthermore, current biochemical studies have revealed mechanisms underlying the limited activity of other agents used in the treatment of medulloblastoma. The minimal activity of nitrosoureas against medulloblastoma is due in large part to the high levels of O6-alkylguanine-DNA alkyltransferase (the protein that repairs methylating and chloroethylating agent-induced adducts) seen in this tumor (Schold et al., 1989; Mineura et al., 1993; Chen et al., 1992; He et al., 1992). The remarkable disease-free survival in children with poor-risk medulloblastoma treated with radiotherapy plus CCNU-cisplatin-vincristine (Packer et al., 1988, 1994b) presumably reflects the extraordinary activity of cisplatin. This study, albeit a single-arm trial with controversial criteria for high-risk assignment, considerably strengthens the belief that chemotherapy should play an important role in treating medulloblastoma in children. A randomized study performed by the German Oncology Group recently confirmed the "excellent" survival rate after treatment with radiotherapy and chemotherapy during and after radiation (Kortmann et al., 2000). To date, no chemotherapy trial has demonstrated a survival benefit for patients treated with pre-radiation chemotherapy (Zeltzer et al., 1999; Kuhl et al., 1998).

The apparent efficacy of chemotherapy in poor or high-risk disease has led some to postulate that combined chemotherapy and reduced-dose craniospinal irradiation may achieve effective disease control in selected average-risk medulloblastoma patients (Kun and Constine, 1991). A recent study completed by the Childrens Cancer Group demonstrated an 80% disease-free survival rate at 3 years after treatment with 23.4 Gy of craniospinal radiotherapy and post-radiotherapy chemotherapy with CCNU, vincristine, and cisplatin (Packer et al., 1999). The current prospective, randomized Childrens Cancer Group and Pediatric Oncology Group trial is testing combined therapy with reduced-dose craniospinal irradiation (23.4 Gy) with one of two post-radiotherapy chemotherapy regimens for children with average-risk disease. The balance of survival and late treatment-related toxicities will be tested in the prospective clinical trial.

A prospective randomized trial in children with poor-risk disease, comparing CCNU and vincristine

chemotherapy to pre-irradiation chemotherapy with the "8-drug-in-1-day" (8-in-1) regimen, has recently been completed. Patients who received the 8-in-1 regimen fared least well (Zeltzer et al., 1999). Other trials that have recently been completed utilizing even higher dose chemotherapy regimens have also not been beneficial (Kuhl et al., 1998). Concomitantly, among children with recurrent medulloblastoma, a subgroup of patients manifests long-term disease control after treatment with high-dose chemotherapy, especially thiotepe-based regimens (Finlay et al., 1996). These patients usually have localized disease at the time of relapse and/or tumors that can be totally resected after relapse.

These studies have resulted in a generation of trials utilizing chemotherapy at higher doses either during or after irradiation in children with poor-risk disease. Trials are ongoing with carboplatin during irradiation, and another trial is now being performed utilizing high-dose chemotherapy, a thiotepe-based regimen with peripheral stem cell rescue support.

Data from the experience with chemotherapy as the primary treatment for medulloblastoma, gathered from children younger than 3 years of age, have been disappointing. Treatment taking the Pediatric Oncology Group ("Baby POG") approach, with alternating cycles of cyclophosphamide, vincristine, and cisplatin VP-16, and studies utilizing a higher dose of treatment by the Childrens Cancer Group, have demonstrated that approximately 20% to 40% of patients, primarily those with localized disease at the time of diagnosis, can be treated with chemotherapy alone (Duffner et al., 1993; Geyer et al., 1994; Packer et al., 1998). For those patients with disseminated disease at the time of diagnosis, chemotherapy-alone regimens have resulted in much poorer disease control. Although many patients treated with chemotherapy will fail after completing treatment, leading to suggestions that radiation therapy be given after a finite period of chemotherapy, a subgroup will fail during chemotherapy, and a subgroup will fail during maintenance chemotherapy. The utility of maintenance chemotherapy for infants who have apparently responded to higher dose induction chemotherapy is questionable. Children with atypical teratoid tumors, who are usually younger than 3 years of age, fare poorly with any form of chemotherapy or radiotherapy (Rorke et al., 1996). More complex regimens utilizing high-dose chemotherapy have not yet been shown to be more effective than less-aggressive reg-

imens (such as the MOPP regimen utilizing mechlorethamine, vincristine, prednisone and procarbazine) (Baram et al., 1987). Studies of high-dose chemotherapy in newly diagnosed patients with peripheral stem cell rescue are being completed. Future therapies are likely to be coupled with focal radiation therapy (Guruangan et al., 1998) or intrathecal chemotherapy to maximize disease control (Dupuis-Girod et al., 1996).

Adult Medulloblastoma

As is the case with children, an increase in 5 and 10 year survival rates has occurred in adults through improved neuroimaging techniques, safer surgery, more precise high-energy radiotherapy equipment, and better chemotherapies (Levin et al., 2001). Statistics gathered on patient survival during the past 40 years are limited by the use of retrospective data analyzed over decades and the different methods and parameters that were applied. Patients in earlier series not only were incompletely staged by today's standards, but, for the purposes of statistical analysis, this limitation is compounded by the myriad treatments that were used in different series. Taken together, these inconsistencies obfuscate the meaningfulness and predictive importance of factors such as extent of resection or tumor spread. Furthermore, treatment of medulloblastoma in adults has not been as well established in clinical trials as it has in children. Whereas this may reflect the increased frequency of occurrence of medulloblastoma in children, another factor is the impact that Childrens Cancer Group (CCG), Pediatric Oncology Group (POG), and International Society of Paediatric Oncology (SIOP) have had on medulloblastoma trials over the years. In addition, some of the chemotherapy approaches used for children, which involves administering multiple doses of vincristine and cisplatinum, may be difficult to complete in adults because of cumulative neurotoxicity. Analyzing data from adult medulloblastoma series dating from the 1960s, with these predominantly occurring from 1970 onward, 5 year survival rates range between 46% and 78%, with an average of approximately 60% (Kopelson et al., 1982; Hughes, 1984; Haie et al., 1985; Cornu et al., 1990; Hartsell et al. 1992; Hazuka et al., 1992; Carrie et al., 1993, 1994; Frost et al. 1995; Prados et al., 1995; Noel et al., 1997; Brandes et al., 1999; Giordana et al., 1999; Chan and Tarbell et al., 2000).

Cerebellar Pilocytic Astrocytomas

Cerebellar astrocytomas encroach on the fourth ventricle. Astrocytic neoplasms of the cerebellum span the full gamut from juvenile pilocytic astrocytomas to glioblastomas. Low-grade cerebellar tumors may occur in adults, but higher grade lesions are somewhat more frequent.

Early recognition of the pilocytic astrocytoma is important because it can be potentially cured through complete surgical excision. The histologic architecture of the pilocytic astrocytoma consists of clustered fascicles of elongated, bipolar neoplastic astrocytes (*pilocyte* literally means "hair cell") interspersed with less cellular, often microcystic, areas of stellate astrocytes (Fig. 6-3). It is also typical to find several markers of chronicity and degeneration, such as Rosenthal fibers, eosinophilic granular bodies ("protein droplets"), and nuclear atypia. The nuclear atypia together with the commonly encountered microvascular proliferation are not negative prognostic factors in pilocytic astrocytomas but may cause pilocytic astrocytomas to be erroneously overgraded as malignant astrocytomas (Fig. 6-4). Noninfiltrative, pilocytic, cerebellar astrocytomas occur primarily in children and constitute approximately 10% to 20% of all childhood primary CNS tumors and 30% to 40% of all posterior fossa tumors (Griffin et al., 1979; Matson, 1956). They occur most commonly during the latter portion of the first decade of life and have a second peak occurrence in the first half of the second decade. There is no clear sex predilection.

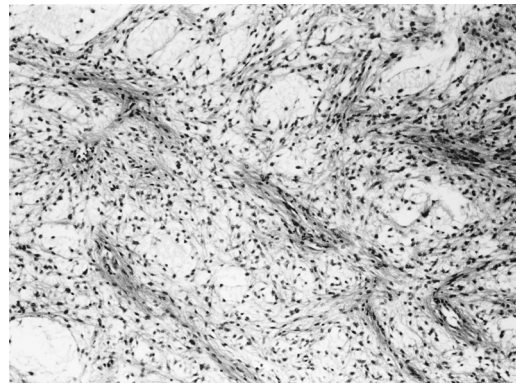


Figure 6-3. Pilocytic astrocytoma. Classic pilocytic astrocytoma architecture is biphasic, with compact areas of neoplastic pilocytes in juxtaposition to loose, microcystic stroma.

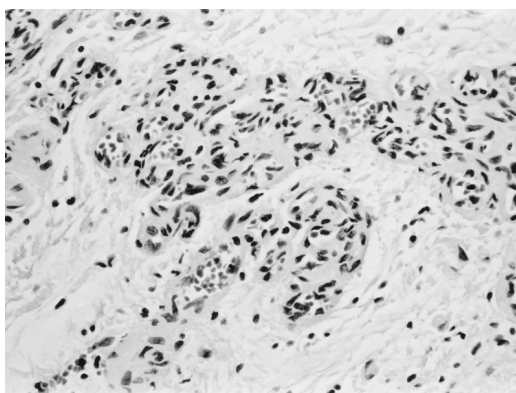


Figure 6-4. Pilocytic astrocytoma. Microvascular proliferation along with degenerative nuclear pleomorphism is commonly seen in pilocytic astrocytomas and constitutes a potential diagnostic pitfall for overgrading.

Fibrillary astrocytomas also occur in the cerebellum and, like their supratentorial counterparts, range from well differentiated to infrequent glioblastomas. It may be difficult to differentiate low-grade fibrillary astrocytomas from pilocytic astrocytomas with limited biopsy samples. Sometimes it is even difficult to distinguish infiltrating cerebellar astrocytomas from ependymic brain stem gliomas.

Presentation

Clinical signs and symptoms of cerebellar astrocytomas depend on the location of the tumor. For tumors that arise in the lateral portion of the cerebellum, unsteadiness and dysmetria predominate early in the course of illness (Griffin et al., 1979; Matson, 1956). Appendicular ataxia, unilateral to the site of the lesion, is then followed by truncal unsteadiness when the tumor or its cyst extends toward the midline. Later in the course of illness, cerebellar deficits are often overshadowed by signs of increased intracranial pressure, which is secondary to blockage of the fourth ventricle and hydrocephalus. The classic symptom of early morning headache, often relieved by nausea and vomiting, then occurs. When the tumor arises in the cerebellar vermis or other midline structures, truncal unsteadiness occurs early in the course of illness followed more rapidly by signs of increased intracranial pressure. In the first few years of life, irritability, anorexia, developmental delay, and, later, regression of intellectual and motor abilities may occur before the recognition of focal neurologic deficits.

At the time of diagnosis, common findings include papilledema, gait ataxia, unilateral or bilateral dysmetria, and cranial nerve abnormalities such as nystagmus or sixth nerve palsies. Head tilt may result from impaction of the cerebellar tonsils into the foramen magnum. Lower extremity hyperreflexia and spasticity may occur secondary to increased intracranial pressure, but are relatively infrequent signs. In infants and very young children, the “sun-setting sign” may be present, manifested by an impaired upgaze and a seemingly forced downward deviation of the eyes.

Surgery

From a surgical perspective, cerebellar tumors can be solid or cystic. Cystic tumors are of three types (Hoffman et al., 1990) (Figs. 6-5 and 6-6). The most common cystic tumor consists of a mural nodule with an associated cyst lined by a glial membrane. The false cystic tumors have a mural nodule with the wall of the cyst also lined by tumor. Another variation is a cyst wall lined by tumor without a mural nodule.

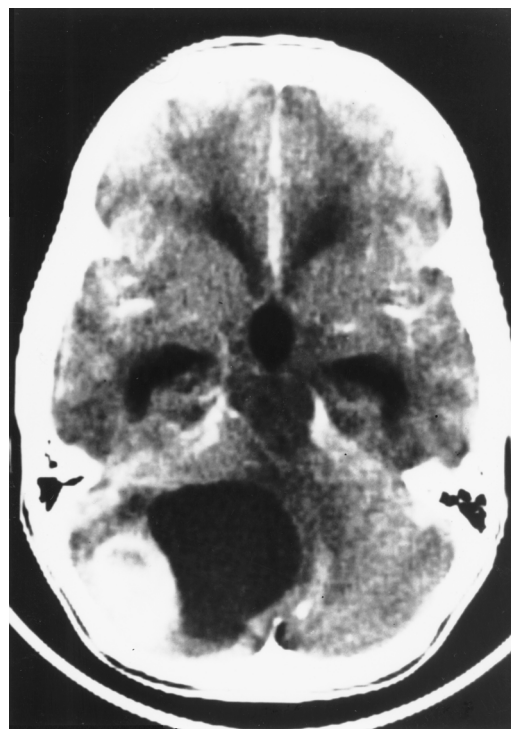

Figure 6-5. Axial enhanced CT scan of child with cystic cerebellar astrocytoma. Note the enhancement of nodule and not of cyst wall.

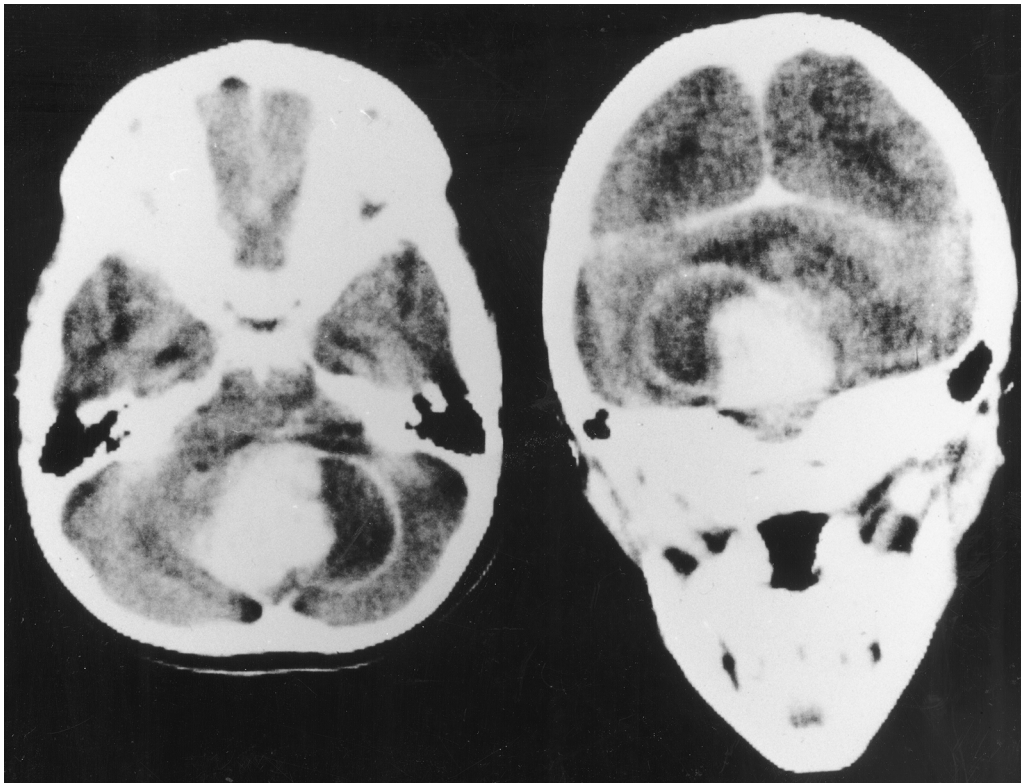


Figure 6-6. Axial and coronal enhanced CT scans of a child with false cystic cerebellar astrocytoma. Note enhancement of both mural nodule and cyst wall.

Radiologically, a distinction can be made between these types of cystic cerebellar astrocytoma because the cyst wall enhances if it is lined by tumor and does not enhance if it is a glial cyst.

Pilocytic cerebellar astrocytomas can normally be totally resected. Recurrences will occur when cystic infiltrative astrocytomas are mistaken for typical cystic pilocytic astrocytomas and part of the tumor cyst wall is left behind. After total resection the vast majority of children will require no further treatment, and 90% to 95% can be expected to be apparently cured. After subtotal resections, especially near-total resections of pilocytic tumors, some will not require further treatment for months or years. At the time of progression in these cases, reoperation and attempts at complete resection are probably indicated before other forms of treatment are initiated.

Radiotherapy

The efficacy of radiotherapy for incompletely resected pilocytic cerebellar astrocytomas is unproven (Leibel

et al., 1975; Garcia et al., 1990). There is no evidence to support the use of radiotherapy for children with totally resected tumors (Geissinger, 1971; Gjerris and Klinken, 1978). Some reports suggest that radiotherapy prolongs the survival rate of patients who have only had a partial resection of tumor, although these are primarily retrospective reviews of patients collected over decades. Because the recurrences of pilocytic astrocytomas are infrequent and usually localized, it seems reasonable to withhold radiotherapy until there are signs of progression. Even at this point, the benefits of repeat resection versus radiotherapy remain uncertain (Leibel et al., 1975; Garcia et al., 1990).

Chemotherapy

Data showing the utility of chemotherapy for childhood pilocytic astrocytomas are even more scant (Edwards et al., 1980). There is no evidence that chemotherapy has a role as adjuvant treatment for children with totally resected tumors or for those chil-

dren with partially resected tumors who then receive radiotherapy. There are scattered, mostly anecdotal, reports of the benefits of chemotherapy for patients with recurrent or progressive symptomatic tumors utilizing drugs such as carboplatin, vincristine, BCNU, and a combination such as TPDCV (6-thioguanine, procarbazine, dibromodulcitol, 1-[2-chloroethyl]-3-cyclohexyl-1-nitrosourea, and vincristine) (Prados et al., 1997; Petronio et al., 1991).

Diffuse, Infiltrating Cerebellar Astrocytomas

Presentation

Infiltrative gliomas of the cerebellum, which are more common in adults than in children (Hayostek et al., 1993), histologically range from low-grade astrocytomas to glioblastoma multiforme. As is the case for noninfiltrative gliomas, presentation depends on the location of the tumor in the cerebellum. In general, low-grade infiltrative astrocytomas tend to present more insidiously than pilocytic astrocytomas and cause greater midline cerebellar deficits early in the course of illness. Later, when the lesion obstructs the fourth ventricle, the more classic symptoms and signs of increased intracranial pressure, such as morning headaches and vomiting, become evident. Patients with higher grade lesions tend to present more explosively. This is especially true for patients with glioblastoma multiforme, as the symptoms and signs of increased intracranial pressure frequently overshadow cerebellar deficits.

At the time of diagnosis, most patients have unilateral or bilateral dysmetria, truncal unsteadiness, and papilledema. A sixth nerve palsy is a frequent finding, whereas other cranial nerve palsies occur less frequently. Other extraocular movement disorders, including ocular dysmetria, ocular flutter, and upbeat nystagmus, are common. Tumors that infiltrate the lower parts of the cerebellar vermis and compress the medullary regions may also cause downbeat nystagmus.

Surgery

Low-grade infiltrative astrocytomas and higher grade cerebellar gliomas tend to be refractory to total surgical resection. For "totally resected," low-grade infiltrative lesions, a period of observation before initiation of further therapy is likely indicated.

Radiotherapy

For those patients with subtotally resected low-grade infiltrative gliomas, there is little evidence that radiotherapy increases the rate of long-term disease control or survival (Leibel et al., 1975; Winston et al., 1977; Garcia et al., 1990). These tumors tend to recur locally, but leptomeningeal spread of these lesions at the time of disease relapse may occur, and patients should probably be staged by MRI of the spine for seeding at the time of local relapse.

Management of patients with higher grade cerebellar gliomas is more difficult. Although the majority of disease relapses occur at the primary tumor site, a significant percentage of patients (greater than 30% in some series) have evidence of leptomeningeal disease at presentation or at the time of progression (Packer et al., 1985). There is some evidence that craniospinal irradiation may be effective in controlling neuraxis disease (Salazar, 1981).

Chemotherapy

Similar to results in patients with high-grade cerebral malignancies, adjuvant chemotherapy may increase the chances of survival (Sposto et al., 1989; Chamberlain et al., 1990).

Brain Stem Gliomas

Brain stem gliomas may occur in any age group; however, approximately 75% of patients who develop such tumors will be younger than 20 years of age at diagnosis (Littman et al., 1980; Edwards et al., 1989; Albright et al., 1983). The peak incidence of these tumors is in the latter half of the first decade of life, and there is no sex predilection. It has been suggested that brain stem gliomas in adults tend to have a somewhat indolent course and are likely to be low grade and localized at the time of diagnosis (Edwards et al., 1989). Brain stem gliomas can generally be divided into three major subtypes: (1) diffuse intrinsic, (2) tectal, and (3) cervicomedullary. Occasionally, a true focal, often pilocytic, intrinsic brain stem glioma is seen (Table 6-2). The differential diagnosis of a brain stem mass is more difficult in adulthood, as metastatic and infectious lesions make up a higher proportion of lesions. Stereotactic biopsy of brain stem lesions has added importance for older patients in whom the vast majority of lesions are gliomas (Masager et al., 2000).

Table 6–2. Brain Stem Gliomas

<i>Type</i>	<i>Presentation</i>	<i>Treatment</i>	<i>Outcome</i>
Diffuse, intrinsic (usually pontine \pm other regions)	Multiple cranial nerve deficits, long tract signs, sensory abnormalities	Surgery usually not indicated; local radiotherapy	10% or less 18 month PFS
Exophytic, cervicomedullary	Headache, vomiting, occasional ataxia and lower cranial nerve deficits	Gross total resection or partial resection plus local radiotherapy	80%–90% 5 year PFS
Focal, midbrain (usually tectal)	Headache, vomiting, hydrocephalus	Cerebrospinal fluid diversion; observation	67% stable for 5 years with other treatment
Focal, intrinsic (usually pontine)	Focal sixth and seventh cranial nerve palsies	Biopsy plus local radiotherapy	80%–90% 5 year PFS

PFS, progression-free survival.

Presentation

Brain stem gliomas tend to present insidiously; however, they will ultimately result in long tract signs, cranial neuropathies, and ataxia. Hydrocephalus and signs of increased intracranial pressure occur in fewer than one-third of patients at the time of diagnosis. In children, nonspecific signs such as headaches and behavioral changes may occur in as many as 50% of patients before diagnosis.

On examination, the sixth and seventh cranial nerves are most frequently involved; but depending on the location of the lesion within the brain stem, other cranial nerves may be impaired. If the brain stem glioma arises low in the medulla, it may cause slight cranial nerve deficits early in the course of illness (Albright et al., 1986). Symptoms of unsteadiness, vomiting, and nonspecific head pain tend to predominate. Later, dysphasia and speech difficulties are present. Less frequently, brain stem tumors may initially present as isolated cranial nerve palsies, including isolated sixth and seventh nerve palsies.

Since the advent of MRI, high midbrain tumors, especially those arising in the tectum, are being diagnosed more readily. Patients with these tumors tend to present with hydrocephalus and may or may not have signs of tectal dysfunction, such as upward gaze paresis, pupils that react better to accommodation than light, lid retraction, and convergence or retraction nystagmus ("Parinaud's syndrome"). Patients with this type of tectal presentation tend to have a long history of minor ocular symptoms and signs, behavioral changes, and, often, school difficulties before diagnosis.

Rarely, cortical symptoms are the presenting sign of brain stem gliomas. These symptoms, including behavioral changes and seizures, are probably due to subthalamic and/or subcortical tumor infiltration.

The median time to diagnosis of brain stem gliomas in older series was 4 to 6 months. With the advent and routine availability of better neuroimaging techniques, especially MRI, most patients are now diagnosed within 3 months of the onset of symptoms.

Various factors have been found to be of prognostic importance for children with diffuse, intrinsic brain stem gliomas (Albright et al., 1986). However, because overall outcome is so poor, the independent significance of a single factor has been questioned. In general, children and adults with longer clinical histories before diagnosis and those with more focal lesions, especially cervicomedullary and midbrain lesions, tend to fare best (Edwards et al., 1989; Albright et al., 1986; Barkovich et al., 1990–1991; Hoffman et al., 1980). The significance of histology, obtained by either open or stereotactic biopsy, remains unsettled. For patients with exophytic lesions, histology seems to impact outcome, and patients with benign histology tend to do better than those with anaplastic or malignant gliomas.

Surgery

In the appropriate clinical setting, diffusely infiltrating brain stem astrocytomas that present classic neuroimaging findings are often not biopsied. Studies of biopsied cases and postmortem specimens show a spectrum of differentiation ranging from low-grade infiltrative astrocytoma to glioblastoma; such findings,

on biopsy, have not been prognostically important in diffuse tumors (Albright et al., 1993). Focal lesions and those arising in adulthood are more problematic, and stereotactic biopsy is often indicated. The diagnostic yield from such procedures is high, and morbidity is relatively low (Massager et al., 2000).

Modern neuroimaging has resulted in better categorization and understanding of brain stem gliomas, and at least some are amenable to surgical resection (Epstein and McLeary, 1986; Stroink et al., 1986). The diffuse intrinsic tumor is the most common brain stem glioma.

The dorsally exophytic brain stem tumors protrude posteriorly from the floor of the fourth ventricle, filling it (Hoffman et al., 1980). These tumors are typically low-grade astrocytomas and occasionally gangliogliomas. Patients present with hydrocephalus and rarely have cranial nerve signs. The bulk of the tumor can be removed, and, with such removal, additional therapy may not be necessary. However, surgery can cause significant morbidity, and it is unclear whether outcome is better for patients treated with radical surgery than with subtotal resection followed by local radiotherapy. In most series, 5 year survival rates after "gross-total" resection or partial resections followed by radiotherapy are in the 80% to 90% range (Epstein and McLeary, 1986).

Focal brain stem tumors occur in a segment of the brain stem, most commonly in the midbrain, especially in the tectum. These are usually solid, but they can be cystic. The majority are low-grade astrocytomas (Fig. 6–7). They are amenable to resection, but some tumors are so indolent that they can be observed without any specific treatment, other than cerebrospinal shunting, for weeks to months after detection. Approximately two-thirds of patients will have stable disease for 4 to 5 years after diagnosis and/or CSF diversion, without any other form of specific therapy (Pollack et al., 1994). Rarely, focal intrinsic pontine and medullary tumors may occur. They also may have an indolent course. Management options include observation, "total" surgical resection (with a risk of significant morbidity), or biopsy/partial resection followed by local radiotherapy.

Radiotherapy

Radiotherapy continues to be the primary treatment for the majority of adults and children with brain stem

gliomas (Kim et al., 1980; Halperin et al., 1989). Most patients with diffuse intrinsic tumors will be treated with conventional or high-dose hyperfractionated radiotherapy and will experience clinical improvement; however, more than 90% of patients will succumb to their disease within 18 months of diagnosis. Hyperfractionated radiotherapy with total doses ranging between 68 and 78 Gy has been utilized for patients with brain stem gliomas (Edwards et al., 1989; Barkovich et al., 1990–1991; Packer et al., 1990). For children and adults with diffuse infiltrative lesions, there is yet no evidence that these higher doses of hyperfractionated radiotherapy result in better long-term tumor control (Edwards et al., 1989; Packer et al., 1990, 1994a). However, the majority of patients with high-grade infiltrative lesions will at least transiently respond to the higher doses of radiotherapy and show objective evidence of tumor shrinkage (Barkovich et al., 1990–1991; Packer et al., 1990). Higher doses of radiotherapy will, in a significant number of patients, cause transient neurologic worsening (Packer et al., 1990). Patients in these hyperfractionated radiotherapy series with localized lesions, especially midbrain masses, and those patients with exophytic lesions, which are histologically low grade, fare better than patients receiving hyperfractionated radiotherapy who have diffuse infiltrative masses (Edwards et al., 1989; Barkovich et al., 1990–1991; Mandell et al., 1999). More recent data suggest that patients with localized lesions or diffusely infiltrative pontine gliomas fare as well as with conventional fractionated doses of radiotherapy (180 cGy fractions) when given a total dose of 54 to 56 Gy.

Chemotherapy

Information concerning chemotherapy for patients with brain stem gliomas is largely based on data from patients treated at the time of recurrence (Rodriguez et al., 1988; Sexauer et al., 1985; Chastagner et al., 1997; Djerassi et al., 1977; Gaynon et al., 1990). Responses to a variety of drugs have been reported, including cisplatin, carboplatin, ifosfamide, CCNU (1-[2-cyclohexyl]-1-nitrosourea), and various drug combinations. Interferon- β has also been shown to be transiently effective in children with recurrent brain stem gliomas. To date, no adjuvant treatment trial, including one using interferon- β , has shown chemotherapy or other forms of adjuvant therapy to

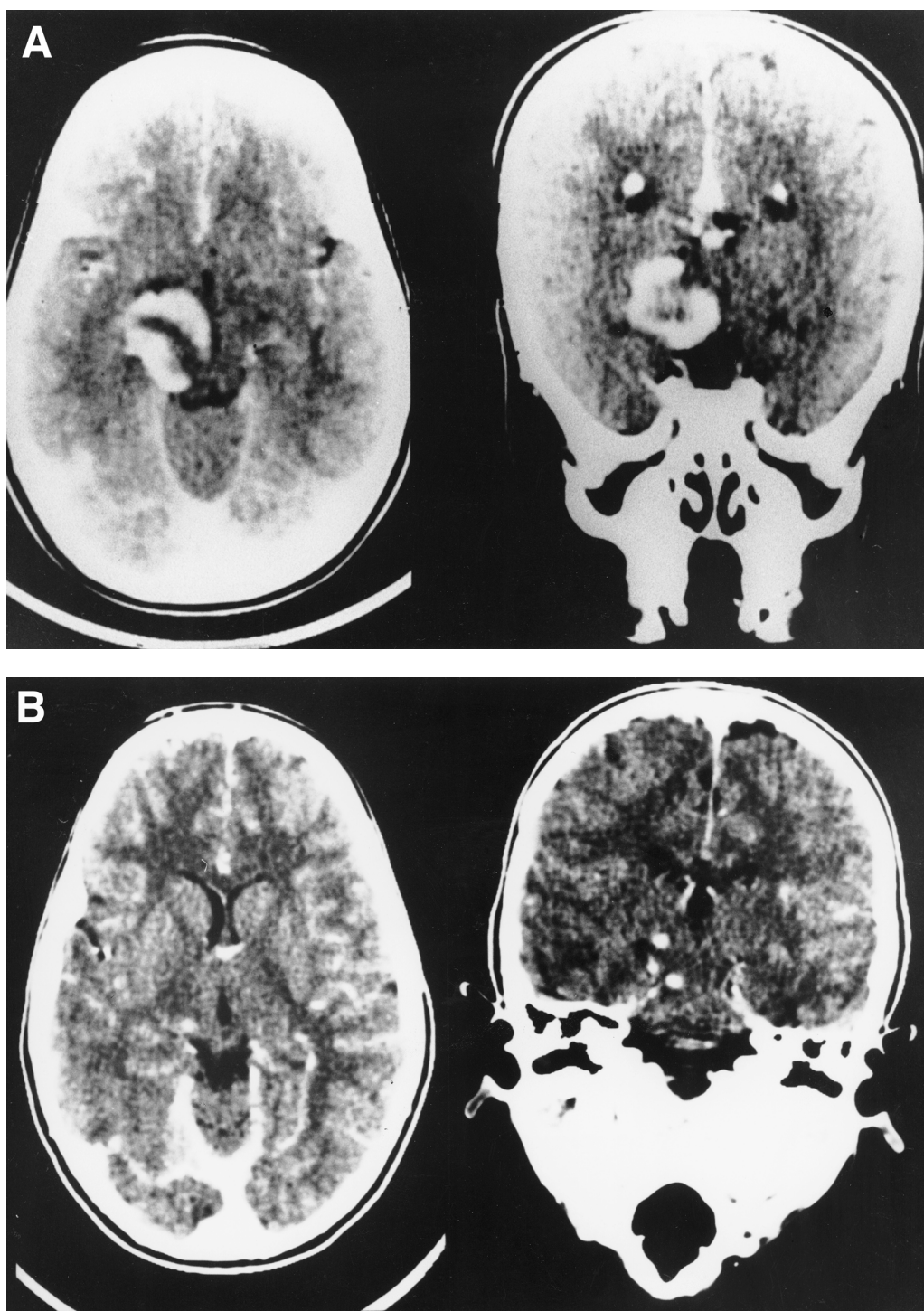


Figure 6–7. (A) Axial and coronal enhanced CT scans of 1-year-old child with focal low-grade midbrain astrocytoma before surgical resection. (B) Axial and coronal enhanced CT scan of same child 4 years after subtotal resection and a course of chemotherapy. The tumor shows a complete response.

be of substantial benefit to survival (Levin et al., 1984b). Exophytic, progressive low-grade tumors may respond to the combination of carboplatin and vincristine (Packer et al., 1997).

Ependymomas

Ependymomas occur in children and adults. In children, approximately two-thirds of ependymomas arise infratentorially and one-third arise supratentorially (Pierre-Kahn et al., 1983; Garret and Simpson, 1983; Wallner et al., 1986; Shaw et al., 1987). The opposite is true for adults. Ependymomas comprise between 10% and 20% of the posterior fossa tumors occurring in patients younger than 15 years of age. In children, ependymomas frequently fill the fourth ventricle and can penetrate the foramen of Luschka and even extend through the foramen of Magendie to the dorsal aspect of the spinal cord.

The two characteristic histologic features of ependymomas are anuclear perivascular collars of radiating cell processes ("perivascular pseudorosettes") and "true" rosettes of tumor cells, which possess a central lumen (Fig. 6–8). Perivascular pseudorosettes are seen more frequently than true rosettes. Immunohistochemically, the glial nature of these neoplasms is reflected in diffuse positivity for S-100 protein. Immunopositivity for glial fibrillary acidic protein is usually focally present, particularly around blood vessels in the cytoplasmic processes that compose the pseudorosettes. Ultrastructural examination often shows such markers of ependymal

lineage as intercellular lumina filled with microvilli and cilia.

Presentation

Ependymomas vary in clinical presentation, and the initial symptoms are usually nonspecific and nonlocalizing (Djohrmann et al., 1976; Mork and Rubinstein, 1985; Pierre-Kahn et al., 1983; Garret and Simpson, 1983; Wallner et al., 1986; Shaw et al., 1987). The effects of increased intracranial pressure, including headaches, may occur early in the course of illness. Alternatively, ependymomas may mimic brain stem lesions and cause multiple cranial nerve palsies before the onset of signs of increased intracranial pressure. Tumors that arise in the cerebellopontine angle will cause unilateral sixth, seventh, and eighth nerve palsies and same-sided limb dysmetria early in illness. Ependymomas may also cause cerebellar deficits and be clinically indistinguishable from medulloblastomas. By and large, infratentorial ependymomas tend to cause symptoms and signs for 2 to 4 months before diagnosis. As these tumors have a tendency to infiltrate the upper portion of the cervical cord, they may also cause neck stiffness and head tilt.

Staging

Frequently, staging studies either before or after surgery are performed on patients with ependymomas, as some patients may have disseminated disease at di-

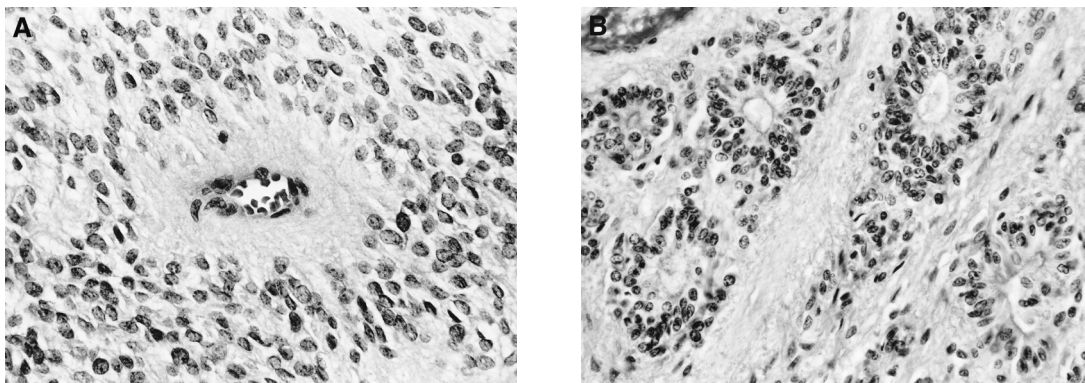


Figure 6–8. Ependymoma. The most characteristic features of most ependymomas are perivascular pseudorosettes (A), which are encountered more frequently than are "true" rosettes (B).

agnosis. Such dissemination is infrequent, occurring in fewer than 10% of patients. Despite this, postoperative (or in some cases preoperative) spinal MRI and CSF cytologic analyses are usually performed.

Surgery

The outcomes of patients who have ependymomas are for the most part proportional to the extent of surgical resection. Patients with totally resected tumors tend to have the best prognosis (Sutton et al., 1991). Approximately one-third of the ependymomas that occur in childhood appear histologically malignant with mitotic figures, pleomorphism, and necrosis. It is unclear if the prognosis for these patients differs from that of patients with less aggressive lesions. Some ependymomas are vascular and infiltrate into surrounding structures or extend into or arise in the cerebellopontine angle enveloping multiple cranial nerves; therefore, they do not lend themselves to total removal. About two-thirds of ependymomas in the posterior fossa have a histologically benign appearance; some of these tumors act aggressively (Pierre-Kahn et al., 1983; Jenkin et al., 1990; Nazar et al., 1990; Horn et al., 1999). If the ependymoma is free of the floor of the fourth ventricle and not intermixed with multiple cranial nerves, it can be totally removed; however, if the ependymoma invades the floor of the fourth ventricle or is wrapped around cranial nerves, it is frequently necessary to leave residual tumor. In such cases, hydrocephalus may continue, and it is therefore important to catheterize the aqueduct of Sylvius to maintain a patent CSF channel and avoid the need for a diversionary ventriculoperitoneal shunt (Jenkin et al., 1990).

Appropriate management for patients with totally resected ependymomas remains unsettled. Approximately 70% of children with totally resected tumors will be alive and free of tumor progression 5 years after surgery and adjuvant radiotherapy (Horn et al., 1999). There is no evidence that the addition of chemotherapy improves outcome. Some have suggested that no adjuvant treatment after total surgical resection is required, but this has not been documented in a prospective randomized study or even in a large retrospective series. The majority of those patients who have been treated with surgery alone have had supratentorial tumors.

Patients with subtotally resected tumors fare less well, with approximately 30% to 40% remaining free

of disease 5 years after treatment with surgery, radiotherapy, and, for some, chemotherapy (Horn et al., 1999). Alternative treatment regimens are currently being evaluated for children with incompletely resected tumors.

Of note is the observation that occasionally residual tumor, following adjuvant therapy, will change in character, and sometimes a tumor that is nonresectable because of infiltration can become totally resectable following irradiation and/or chemotherapy.

Radiotherapy

Postoperative irradiation is a standard treatment for ependymomas. Long-term survival following surgery alone has been infrequent. Reports from the past 20 years indicate disease-free survival rates of 0% to 20% after surgical resection alone (Mork and Loken, 1977; Tomita et al., 1988a; Healey et al., 1991). These studies preceded the MRI era, making determinations of extent of resection and "total resection" less exact. Small series and case reports suggest a more favorable outcome after "total" resections alone, documented by MRI. Despite meaningfully higher disease control rates of 30% to 60% reported with postoperative irradiation, the pattern of failure for both differentiated ependymoma and anaplastic ependymoma remains overwhelmingly one of local recurrence (Goldwein et al., 1990b, 1991; Nazar et al., 1990; Rousseau et al., 1994).

There is continuing debate regarding the appropriate volume of radiotherapy to use in the treatment of ependymomas. The incidence of neuraxis dissemination is remarkably consistent in major series, reported at the 10% level. Tumor recurrence at the primary site usually precedes or occurs concurrently with tumor growth in the neuraxis; intracranial or CSF dissemination is rare as an initial post-treatment event (Kun, 1983; Bloom and Bessel, 1990; Goldwein et al., 1990a,b, 1991; Nazar et al., 1990; Vanuytsel and Brada, 1991; Rousseau et al., 1994). There does appear to be a higher frequency of subarachnoid seeding at diagnosis and at the time of initial failure in children younger than 3 years old (Tomita et al., 1988b; Duffner et al., 1993).

The relatively low rate of neuraxis involvement and the equivalent outcome in series comparing local versus full craniospinal irradiation argue strongly for restricting the radiation volume to the posterior fossa in children with ependymomas (Goldwein et al.,

1990b; Nazar et al., 1990; Shaw et al., 1987; Tomita et al., 1988b; Vanuytsel et al., 1992). The uncertain implication of high histologic grade (or anaplastic ependymoma) similarly favors the use of local fields (Rawlings et al., 1988; Goldwein et al., 1991; Rousseau et al., 1994). Only a prospective trial conducted to assess the local failure rate versus neuraxis failure rate following local posterior fossa irradiation will provide definitive information to clarify this aspect of radiotherapy. Even more localized irradiation, using conformal fields or fractionated stereotactic radiotherapy, have been recently utilized. The effects of such treatments are still under investigation.

Based on dose-response analyses for ependymomas, the typical radiation dose is between 50 and 55 Gy locally (Goldwein et al., 1990b; Vanuytsel et al., 1992; Rousseau et al., 1994). The high rate of local failure following incomplete resection has stimulated ongoing investigations of high-dose, hyperfractionated irradiation and precision-volume stereotactic radiosurgical "boosts" to residual disease sites.

Chemotherapy

The role of chemotherapy in the treatment of ependymomas is poorly defined, although a number of drug therapies have been tried. For patients with recurrent diseases, these therapies have been found to be primarily palliative unless preceded by or associated with "total" re-resections. A variety of different chemotherapeutic agents, including BCNU (1,3-bis-[2-chloroethyl]-1-nitrosourea), dibromodulcitol, cisplatin, ifosfamide, VP 16, and carboplatin, have been effective in the treatment of ependymomas at recurrence (Khan et al., 1982; Levin et al., 1984a, 2001; Miser et al., 1989; Robertson et al., 1998). Occasionally, patients can undergo prolonged remission after first recurrence and treatment with chemotherapy and reoperation. To date, however, there is no evidence that patients with infratentorial ependymomas benefit from adjuvant chemotherapy (Lefkowitz et al., 1989; Robertson et al., 1998). Children younger than 3 years of age, treated with alternating vincristine-cyclophosphamide and cisplatin-etoposide combinations following surgery, exhibited a 2 year PFS of 42%, permitting delayed radiotherapy (Duffner et al., 1993). However, it is unclear whether disease control was due to chemotherapy or was secondary to the degree of surgical resection. Clinical trials are now being conducted to evaluate the possi-

ble use of adjuvant chemotherapy, either before or after radiotherapy, for patients with subtotally resected infratentorial lesions.

OTHER TUMORS

Subependymomas

Subependymomas are rare tumors that may arise in the fourth ventricle. Initially, the majority of subependymomas were discovered in adults as an incidental finding at the time of autopsy, but with the advent of modern neuroimaging techniques, a higher percentage of patients are being diagnosed antemortem. These tumors exhibit a histologic cluster pattern, consisting of groups of benign-appearing, round to oval nuclei in a delicate fibrillary matrix (Fig. 6-9). Some tumors show prominent cystic change; and foci of calcification, hemorrhage, and other degenerative phenomena may be seen. All cases show immunopositivity for S-100 protein and glial fibrillary acidic protein. Ultrastructurally, ependymomal differentiation may be present. A subset of subependymomas exhibits foci of unequivocal ependymoma, which follow a more aggressive course similar to that of ependymomas.

Presentation

Whereas most subependymomas are asymptomatic, symptoms can occur when the tumor arises in the

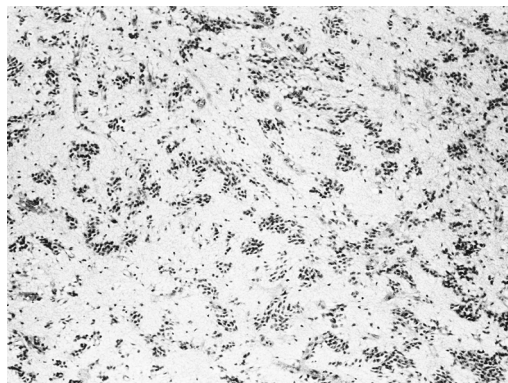


Figure 6-9. Subependymoma. The distinctive morphology of this low-grade neoplasm consists of clustered glial nuclei in a fibrillary stroma composed of cell processes.

fourth ventricle and produces obstructive hydrocephalus. The most common symptoms and signs are nystagmus, headaches, and vomiting; cranial nerve deficits and focal cerebellar signs are less frequent. Occasionally tumors can have elements of subependymomas intermixed with more prominent classic ependymal elements; while the intermixture of the two is common, the preponderance of the ependymal elements may alter the prognosis, which may approximate the fate of children with ependymomas.

Treatment

The treatment of choice for symptomatic tumors is surgical resection (Jooma et al., 1985). For patients with pure subependymomas, there is as yet little evidence that adjuvant radiotherapy or chemotherapy are beneficial. There is also little experience in the treatment of subependymomas with chemotherapy at the time of disease recurrence.

Choroid Plexus Papillomas

Normal choroid plexus consists of fibrovascular cores of connective tissue covered by modified ependymal cells ("choroid epithelium"). Choroid plexus papillomas closely mimic this architecture. These rare tumors arise from the choroid plexus of the fourth ventricle. They can be benign with no evidence of invasion and, thus, can be easily removed. Less histologic similarity to normal choroid plexus is found in the rarer choroid plexus carcinomas (Fig. 6–10), which can invade widely and metastasize.

Total surgical resection without additional therapy results in long-term disease control for children with choroid plexus papillomas and for some patients with carcinomas (Packer et al., 1992; Chow et al., 1999). The utility of adjuvant radiotherapy or chemotherapy for incompletely resected lesions, including carcinomas, has not been proved in a prospective clinical trial. Recently, however, Wolff and colleagues (1999) reported a retrospective analysis of 48 patients with choroid plexus carcinoma and total tumor resection, of whom one-half received postsurgical irradiation. They found a 5 year survival of 68% for the irradiated group compared with 16% for the nonirradiated group. Whereas the nonirradiated group was younger (median, 1.6 years) than those irradiated (median 3.9 years), they observed that older irradiated patients survived longer than younger patients. Subto-

tally resected or recurrent carcinomas may respond to radiotherapy or chemotherapy, but long-term disease control is usually poor (Packer et al., 1992; Duffner et al., 1993).

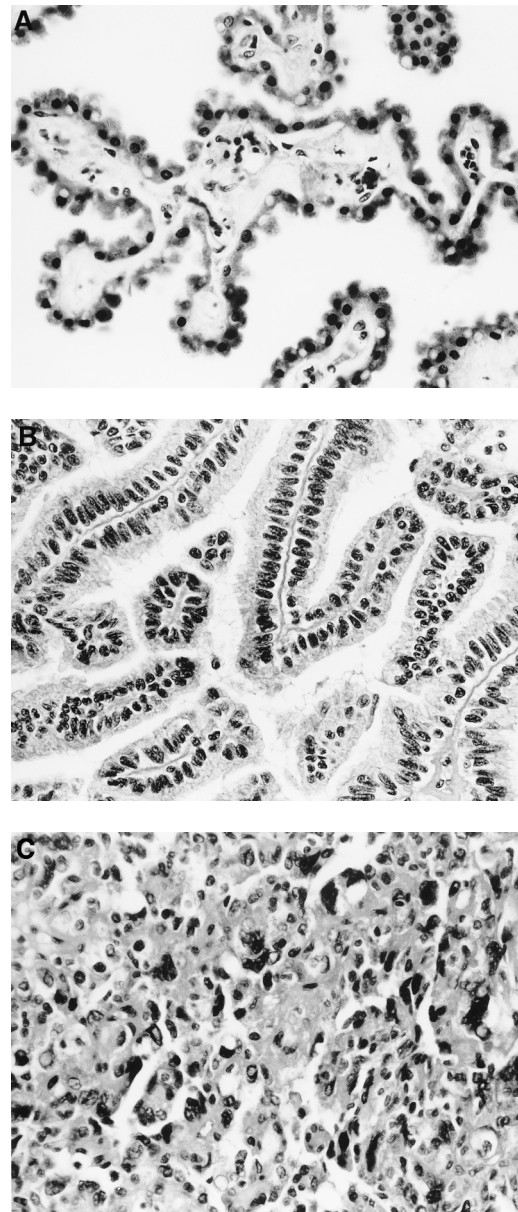


Figure 6–10. Choroid plexus papilloma. The architecture of normal choroid plexus (A) is closely mimicked by the choroid plexus papilloma (B) but significantly effaced in the rarer choroid plexus carcinoma (C).

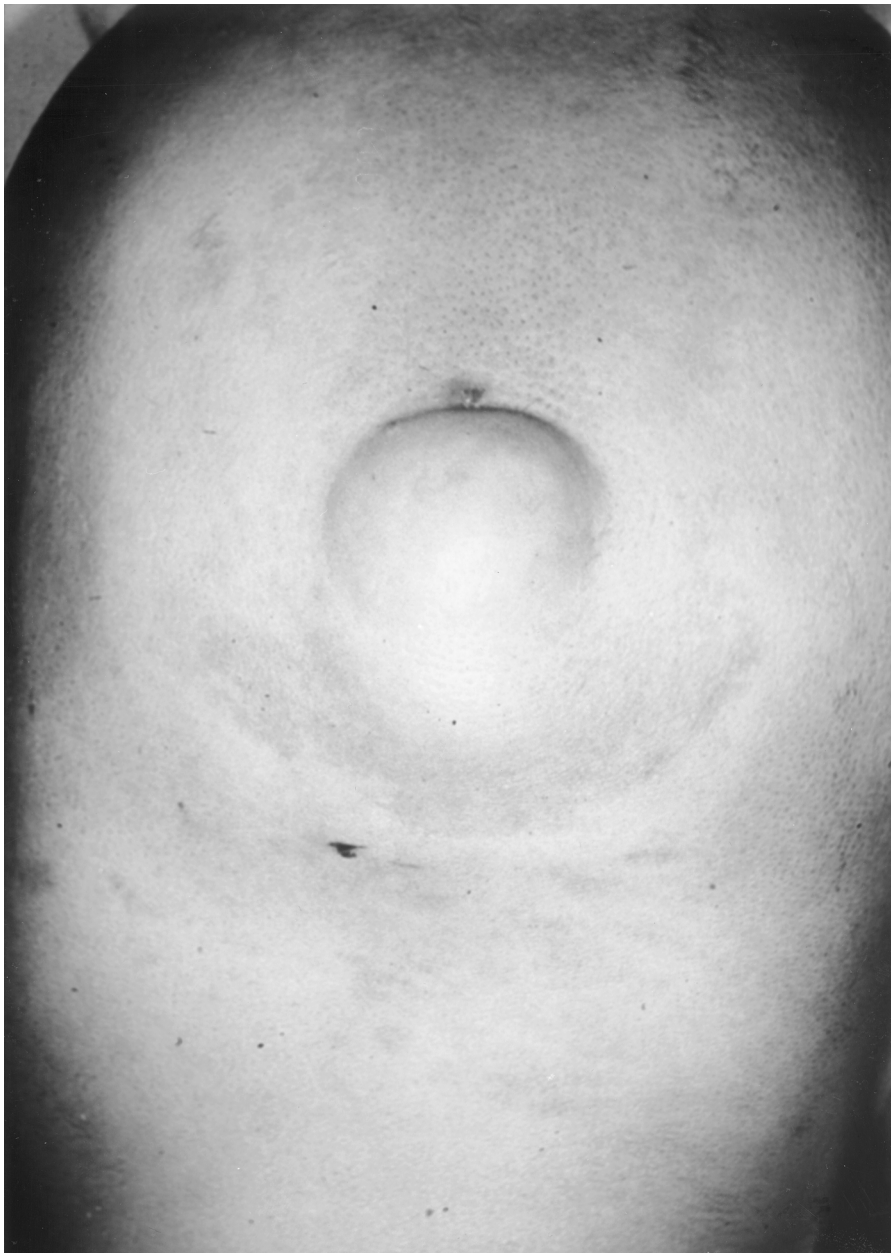

Figure 6-11. View of occiput of child with occipital dermal sinus and subcutaneous dermoid tumor, which extended through the calvarium and ended in a fourth ventricular dermoid tumor.

Dermoid Tumors

Dermoid tumors typically are midline tumors that in the posterior fossa occupy the vermis and encroach on the fourth ventricle (Fig. 6-11) and are usually associated with a dermal sinus, which typically runs in a caudal direction from a skin dimple near the in-

ion. If a dimple is visualized in a child's occipital region, neuroimaging should be conducted to rule out an intracranial dermoid tumor. Dimples such as these are usually covered with hair and are frequently undetected until the child presents with a septic meningitis or until the tumor is precipitously enlarged due to abscess formation.

CONCLUSIONS

More than one-third of patients with fourth ventricular tumors, especially those with pilocytic cerebellar astrocytomas, will have a benign course, and their disease can be managed without adjuvant radiotherapy or chemotherapy. More than 50% of the malignant tumors of the fourth ventricle, especially medulloblastomas, are curable with modern techniques of radiotherapy and chemotherapy. Modern neuroimaging has led to earlier diagnosis and better understanding of the anatomy of such lesions by the neurosurgeon, and modern surgical tools have allowed the neurosurgeon to safely excise fourth ventricular tumors in a manner not possible in the past. Focal radiotherapy techniques are being studied for posterior fossa tumors. The role of chemotherapy is being better defined and, for medulloblastoma, is being expanded.

REFERENCES

- Albright AL, Guthkelch AN, Packer RJ, Price RA, Rourke LB. 1986. Prognostic factors in pediatric brain-stem gliomas. *J Neurosurg* 65:751-755.
- Albright AL, Packer RJ, Zimmerman R, Rorke LB, Byett J, Hammond GD. 1993. Magnetic resonance scans should replace biopsies for the diagnosis of diffuse brain stem gliomas: a report from the Children's Cancer Group. *Neurosurgery* 33:6:1026-1030.
- Albright A, Price RA, Guthkelch AN. 1983. Brain stem gliomas of children. A clinicopathological study. *Cancer* 52:2313-2319.
- Allen JC, Donahue B, DaRosso R, Nirenberg A. 1996. Hyperfractionated craniospinal radiotherapy and adjuvant chemotherapy for children with newly diagnosed medulloblastoma and other primitive neuroectodermal tumors. *Int J Radiat Oncol Biol Phys* 36:1155-1161.
- Baram TZ, van Eys J, Dowell RE, Cangir A, Pack B, Bruner JM. 1987. Survival and neurologic outcome of infants with medulloblastoma treated with surgery and MOPP chemotherapy. A preliminary report. *Cancer* 60:173-177.
- Barkovich AJ, Krischer J, Kun LE, et al. 1990-1991. Brain stem gliomas: a classification system based on magnetic resonance imaging. *Pediatr Neurosurg* 16:73-83.
- Bloom HJ, Glee J, Bell J, Ashley SE, Gorman C. 1990. The treatment and long-term prognosis of children with intracranial tumors: a study of 610 cases, 1950-1981. *Int J Radiat Oncol Biol Phys* 18:723-745.
- Bloom HG, Bessell EM. 1990. Medulloblastoma in adults: a review of 47 patients treated between 1952 and 1981. *Int J Radiat Oncol Biol Phys* 18:763-777.
- Brandes AA, Palmisano V, Monfardini S. 1999. Medulloblastoma in adults: clinical characteristics and treatment. *Cancer Treat Rev* 25:3-12.
- Carrie C, Lasset C, Alapetite C. 1994. Multivariate analysis of prognostic factors in adult patients with medulloblastoma. Retrospective study of 156 patients. *Cancer* 74:2352-2360.
- Carrie C, Lasset C, Blay JY, et al. 1993. Medulloblastoma in adults: survival and prognostic factors. *Radiation Oncol* 29:301-307.
- Chamberlain MC, Silver P, Levin VA. 1990. Poorly differentiated gliomas of the cerebellum. A study of 18 patients. *Cancer* 65:337-340.
- Chan AW, Tarbell NJ, Black PM, et al. 2000. Adult medulloblastoma: prognostic factors and patterns of relapse. *Neurosurgery* 47:623-631.
- Chastagner P, Bracard S, Sommelet-Olive D, et al. 1997. Analysis of the treatment response and survival rate in two sequential series of 74 brain stem gliomas (BSG) treated in a single centre. *Proc Annu Meet Am Soc Clin Oncol* 16:A1419.
- Chen JM, Zhang YP, Wang C, Sun Y, Fujimoto J, Ikenaga M. 1992. O6-methylguanine-DNA methyltransferase activity in human tumors. *Carcinogenesis* 13:1503-1507.
- Chow E, Reardon DA, Shah AB, et al. 1999. Pediatric choroid plexus neoplasms. *Int J Radiat Oncol Biol Phys* 44:249-254.
- Cornu P, Chatellier G, Fauchon F, et al. 1990. The prognosis of medulloblastoma in adults. *Neurochirurgie* 36:218-224.
- Cushing H. 1930. Experiences with the cerebellar medulloblastoma. A critical review. *Acta Pathol Microbiol Scand* 7:1.
- Deutsch M. 1988. Medulloblastoma: staging and treatment outcome. *Int J Radiat Oncol Biol Phys* 14:1103-1107.
- Deutsch M, Thomas PR, Krischer J, et al. 1996. Results of a prospective randomized trial comparing standard dose neuraxis irradiation (3,600 cGy/20) with reduced neuraxis irradiation (2,340 cGy/13) in patients with low-stage medulloblastoma: a combined Children's Cancer Group-Pediatric Oncology Group Study. *Pediatr Neurosurg* 24:167-176.
- Djerassi I, Kim JS, Shulman K. 1977. High-dose methotrexate-cytovorum factor rescue in the management of brain gliomas. *Cancer Treat Rep* 61:691-694.
- Djohrmann GJ, Farwell JR, Flannery JT. 1976. Ependymomas and ependymoblastomas in children. *J Neurosurg* 45:273-283.
- Duffner PK, Horowitz ME, Krischer JP, et al. 1993. Postoperative chemotherapy and delayed radiation in children less than three years of age with malignant brain tumors. *N Engl J Med* 328:1725-1731.
- Dupuis-Girod S, Hartmann O, Berhamou E, et al. 1996. Will high dose chemotherapy followed by autologous bone marrow transplantation supplant cranio-spinal irradiation in young children treated for medulloblastoma? *J Neurooncol* 27:87-98.
- Edwards MS, Levin VA, Wilson CB. 1980. Chemotherapy of pediatric posterior fossa tumors. *Childs Brain* 7:252-260.
- Edwards MS, Wara WM, Urtasun RC, et al. 1989. Hyperfractionated radiation therapy for brain-stem glioma: a phase I-II trial. *J Neurosurg* 70:691-700.
- Epstein F, McCleary EL. 1986. Intrinsic brain-stem tumors of childhood: surgical indications. *J Neurosurg* 64:11-15.
- Evans AE, Jenkin RD, Spoto R, et al. 1990. The treatment of medulloblastoma. Results of a prospective randomized trial of radiation therapy with and without CCNU, vincristine and prednisone. *J Neurosurg* 72:572-582.

- Fertil B, Malaise EP. 1985. Intrinsic radiosensitivity of human cell lines is correlated with radioresponsiveness of human tumors: analysis of 101 published survival curves. *Int J Radiat Oncol Biol Phys* 11:1699-1707.
- Finlay JL, Goldman S, Wong MC, et al. 1996. Pilot study of high-dose thiotepa and etoposide with autologous bone marrow rescue in children and young adults with recurrent CNS tumors. The Children's Cancer Group. *J Clin Oncol* 14:2495-2503.
- Friedman HS, Colvin OM, Skapek SX, et al. 1988. Experimental chemotherapy of human medulloblastoma cell lines and transplantable xenografts with bifunctional alkylating agents. *Cancer Res* 48:4189-4195.
- Friedman HS, Dolan ME, Moschel RC, et al. 1992. Enhancement of nitrosourea activity in medulloblastoma and glioblastoma multiforme. *J Natl Cancer Inst* 84:1926-1931.
- Friedman HS, Oakes WJ. 1987. The chemotherapy of posterior fossa tumors in childhood. *J Neurooncol* 5:217-229.
- Friedman HS, Schold SC Jr, Mahaley MS Jr, et al. 1989. Phase II treatment of medulloblastoma and pineoblastoma with melphalan: clinical therapy based on experimental models of human medulloblastoma. *J Clin Oncol* 7:904-911.
- Frost PJ, Laperriere NJ, et al. 1995. Medulloblastoma in adults. *Int J Radiat Oncol Biol Phys* 32:851-957.
- Gajjar A, Fouladi M, Walter AW, et al. 1999. Comparison of lumbar and shunt cerebrospinal fluid specimens for cytologic detection of leptomeningeal disease in pediatric patients with brain tumors. *J Clin Oncol* 17:1825-1828.
- Garcia DM, Marks JE, Latifi HR, Klieforth AB. 1990. Childhood cerebellar astrocytomas: is there a role for postoperative irradiation? *Int J Radiat Oncol Biol Phys* 18:815-818.
- Garrett PG, Simpson WJ. 1983. Ependymomas: results of radiation treatment. *Int J Radiat Oncol Biol Phys* 9:1121-1124.
- Gaynon PS, Ettinger LJ, Baum ES, Siegel SE, Krailo MD, Hammond GD. 1990. Carboplatin in childhood brain tumors. A Children's Cancer Study Group phase II trial. *Cancer* 66:2465-2469.
- Geissinger J. 1971. Astrocytomas of the cerebellum in children: long term study. *Arch Neurol* 24:125-135.
- Geyer JR, Zeltzer PM, Boyett JM, et al. 1994. Survival of infants with primitive neuroectodermal tumors of malignant ependymomas of the CNS treated with eight-drugs-in-1-day: a report from the Children's Cancer Group. *J Clin Oncol* 12:1607-1615.
- Giordana MT, Schiffer P, Lanotte M, Girardi P, Chio A. 1999. Epidemiology of adult medulloblastoma. *Int J Cancer* 80:689-692.
- Gjerris F, Klinken L. 1978. Long-term prognosis in children with benign cerebellar astrocytoma. *J Neurosurg* 49:179-184.
- Goldwein JW, Corn BJ, Finlay JL, Packer RJ, Rorke LB, Schut L. 1991. Is craniospinal irradiation required to cure children with malignant (anaplastic) ependymomas? *Cancer* 67:2766-2771.
- Goldwein JW, Glauser TA, Packer RJ, et al. 1990a. Recurrent intracranial ependymomas in children. Survival, patterns of failure, and prognostic factors. *Cancer* 66:557-563.
- Goldwein JW, Leahy JM, Packer RJ, et al. 1990b. Intracranial ependymomas in children. *Int J Radiat Oncol Biol Phys* 19:1497-1502.
- Griffin TW, Beaufait D, Blasko JC. 1979. Cystic cerebellar astrocytomas in childhood. *Cancer* 44:276-280.
- Grotzer MA, Janss AJ, Fung K-M, et al. 2000. TrkC expression predicts good clinical outcome in primitive neuroectodermal brain tumors. *J Clin Oncol* 18:1027-1035.
- Guruangan S, Dunkel IJ, Goldman S, et al. 1998. Myeloablative chemotherapy with autologous bone marrow rescue in young children with recurrent malignant brain tumors. *J Clin Oncol* 16:2486-2493.
- Haie C, Schlienger M, Constans JP, Meder JF, Reynaud A, Ghenim C. 1985. Results of radiation treatment of medulloblastoma in adults. *Int J Radiat Oncol Biol Phys* 11:2051-2056.
- Halberg FE, Wara WW, Fippin LF, et al. 1991. Low-dose craniospinal radiation therapy for medulloblastoma. *Int J Radiat Oncol Biol Phys* 20:651-654.
- Halperin EC, Wehn SM, Scott JW, Djang W, Oakes WJ, Friedman HS. 1989. Selection of a management strategy for pediatric brainstem tumors. *Med Pediatr Oncol* 17:117-126.
- Hartsell WF, Montag AG, Lydon J, Galinsky DL, Sarin P. 1992. Treatment of medulloblastoma in adults. *Am J Clin Oncol* 15:207-211.
- Hayostek CJ, Shaw EG, Scheithauer B, et al. 1993. Astrocytomas of the cerebellum. *Cancer* 72:855-868.
- Hazuka MB, DeBiose DA, Henderson RH, Kinzie JJ. 1992. Survival results in adult patients treated for medulloblastoma. *Cancer* 69:2143-2148.
- He XM, Ostrowski LE, von Wronski MA, et al. 1992. Expression of O6-methylguanine-DNA methyltransferase in six human medulloblastoma cell lines. *Cancer Res* 52:1144-1148.
- Healey EA, Barnes PD, Kupsky WJ, et al. 1991. The prognostic significance of postoperative residual tumor in ependymoma. *Neurosurgery* 28:666-671.
- Hoffman HJ, Becker L, Craven MA. 1980. A clinically and pathologically distinct group of benign brain stem gliomas. *Neurosurgery* 7:243-248.
- Hoffman HJ, Berger MS, Becker LE. 1990. Cerebellar astrocytomas. In: Deutsch M (ed), *Management of Childhood Brain Tumors*. Boston: Kluwer Academic Publishers, 523 p.
- Hoffman HJ, Hendrick EB, Humphreys RP. 1976. Metastasis via ventriculoperitoneal shunt in patients with medulloblastoma. *J Neurosurg* 44:562-566.
- Horn B, Heideman R, Geyer R, et al. 1999. A multi-institutional retrospective study of intracranial ependymoma in children: identification of risk factors. *J Pediatr Hematol Oncol* 21:203-211.
- Hughes EN, Shillito J, Sallan SE, Loeffler JS, Cassady JR, Tarbell NJ. 1988. Medulloblastoma at the Joint Center for Radiation Therapy between 1968 and 1984. The influence of radiation dose on the patterns of failure and survival. *Cancer* 61:1992-1998.
- Hughes PG. 1984. Cerebellar medulloblastoma in adults. *J Neurosurg* 60:994-997.
- Jenkin D, Goddard K, Armstrong D, et al. 1990. Posterior fossa medulloblastoma in childhood: treatment results and a proposal for a new staging system. *Int J Radiat Oncol Biol Phys* 19:265-274.

- Jooma R, Torrens MJ, Bradshaw J, Brownell B. 1985. Subependymomas of the fourth ventricle. Surgical treatment in 12 cases. *J Neurosurg* 62:508-512.
- Khan AB, D'Souza BJ, Wharam MD, et al. 1982. Cisplatin therapy in recurrent childhood brain tumors. *Cancer Treat Rep* 66:2013-2020.
- Kim TH, Chin HW, Pollan S, Hazel JH, Webster JH. 1980. Radiotherapy of primary brain stem tumors. *Int J Radiat Oncol Biol Phys* 6:51-57.
- Kleihues P, Cavenee W. 2000. Pathology and Genetics of Tumors of the Nervous System. Lyon: IARC Press.
- Kortmann RD, Kuhl J, Timmermann B, et al. 2000. Postoperative neoadjuvant chemotherapy before radiotherapy as compared to immediate radiotherapy followed by maintenance chemotherapy in the treatment of medulloblastoma in childhood: results of the German prospective randomized trial HIT '91. *Int J Radiat Oncol Biol Phys* 46:269-279.
- Kopelson G, Linggood RM, Kleinman GM. 1982. Medulloblastoma in adults: improved survival with supravoltage radiation therapy. *Cancer* 49:1334-1337.
- Krischer JP, Ragab AH, Kun L, et al. 1991. Nitrogen mustard, vincristine, procarbazine, and prednisone as adjuvant chemotherapy in the treatment of medulloblastoma. A Pediatric Oncology Group study. *J Neurosurg* 74:905-909.
- Kuhl J, Muller HL, Berthold F, et al. 1998. Preradiation chemotherapy of children and young adults with malignant brain tumors: results of the German pilot trial HIT '88/'89. *Klin Padiatr* 210:227-233.
- Kun LE. 1983. Patterns of failure in tumors of the central nervous system. *Cancer Treat Symp* 2:285.
- Kun LE, Constine LS. 1991. Medulloblastoma—caution regarding new treatment approaches. *Int J Radiat Oncol Biol Phys* 20:897-899.
- Kun LE, Fontanesi J, Kovnar EH, et al. 1990. Hyperfractionated craniospinal irradiation: a phase I trial in children with malignant central nervous system tumors. *Pediatr Neurosurg* 16:112.
- Lefkowitz I, Evans A, Spoto R, et al. 1989. Adjuvant chemotherapy of childhood posterior fossa (PF) ependymoma: craniospinal radiation with or without CCNU, vincristine (VCR) and prednisone (P). *Proc Am Soc Clin Oncol* 8:878.
- Leibel SA, Sheline GE, Wara WM, Boldrey EB, Hielsen SL. 1975. The role of radiation therapy in the treatment of astrocytomas. *Cancer* 35:1551-1557.
- Levin VA, Edwards MS, Gutin PH, et al. 1984a. Phase II evaluation of dibromodulcitol in the treatment of recurrent medulloblastoma, ependymoma, and malignant astrocytoma. *J Neurosurg* 61:1063-1068.
- Levin VA, Edwards MS, Wara WM, Allen J, Ortega J, Vestnys P. 1984b. 5-Fluorouracil and 1-(2-chloroethyl)-cyclohexyl-1-nitrosourea (CCNU) followed by hydroxyurea, misonidazole, and irradiation for brain stem gliomas: a pilot study of the Brain Tumor Research Center and the Children's Cancer Group. *Neurosurg* 14:679-681.
- Levin VA, Leibel SA, Gutin PH. 2001. Neoplasms of the central nervous system. In: DeVita VT Jr, Hellman S Jr, Rosenberg SA (eds), *Cancer: Principles and Practice of Oncology*, 6th ed. Philadelphia: Lippincott-Raven.
- Levin VA, Rodriguez LA, Edwards MS, et al. 1988. Treatment of medulloblastoma with procarbazine, hydroxyurea, and reduced radiation doses to whole brain and spine. *J Neurosurg* 68:383-387.
- Littman P, Jarrett P, Bilaniuk LT, et al. 1980. Pediatric brain stem gliomas. *Cancer* 45:2787-2792.
- Mandell LR, Kadota R, Freeman C. 1999. There is no role for hyperfractionated radiotherapy in the management of children with newly diagnosed diffuse intrinsic brainstem tumors: results of a Pediatric Oncology Group phase III trial comparing conventional vs. hyperfractionated radiotherapy. *Int J Radiation Oncology Biol Phys* 43:959-964.
- Massager N, David P, Goldman S, et al. 2000. Combined magnetic resonance imaging- and positron emission tomography-guided stereotactic biopsy in brainstem mass lesions: diagnostic yield in a series of 30 patients. *J Neurosurg* 93:951-957.
- Matson D. 1956. Cerebellar astrocytoma in childhood. *Pediatrics* 18:150-155.
- Mineura K, Izumi I, Watanabe K, et al. 1993. Influence of O6-methylguanine-DNA methyltransferase activity on chloroethylnitrosourea chemotherapy in brain tumors. *Int J Cancer* 55:76-81.
- Miser J, Krailo M, Smithson W, et al. 1989. Treatment of children with recurrent brain tumors with ifosfamide (ifos), etoposide (VP-16), and mesna (M): results of a phase II trial. *Proc Am Soc Clin Oncol* 8:84.
- Mork SJ, Loken AC. 1977. Ependymoma. A follow-up study of 101 cases. *Cancer* 40:907-915.
- Mork SJ, Rubinstein LJ. 1985. Ependymoblastoma. A reappraisal of a rare embryonal tumor. *Cancer* 55:1536-1542.
- Nazar GB, Hoffman HJ, Becker LE, Jenkin D, Humphreys RP, Hendrick EB. 1990. Infratentorial ependymomas in childhood: prognostic factors and treatment. *J Neurosurg* 72:408-417.
- Noel G, J Merrer. 1997. Medulloblastoma in adults. Val-de-Grade hospital experience (1975-1994) and literature review. *Cancer Radiother* 1:60-67.
- Packer RJ, Allen JC, Goldwein JL, et al. 1990. Hyperfractionated radiotherapy for children with brainstem gliomas: a pilot study utilizing 7,200 cGy. *Ann Neurol* 27:167-173.
- Packer RJ, Ater J, Allen J, et al. 1997. Carboplatin and vincristine chemotherapy for children with newly diagnosed progressive low-grade gliomas. *J Neurosurg* 86:747-754.
- Packer RJ, Boyett JM, Zimmerman RA, et al. 1994a. Outcome of children with brain stem gliomas after treatment with 7800 cGy of hyperfractionated radiotherapy: a Children's Cancer Group phase I/II Trial. *Cancer* 74:1827-1834.
- Packer RJ, Geyer R, Jennings M, et al. 1998. Disease control in infants and young children with medulloblastomas and ependymomas using chemotherapy alone: a Children's Cancer Group study. *Ann Neurol* 44:537.
- Packer RJ, Goldwein J, Nicholson HS, et al. 1999. Treatment of children with medulloblastomas with reduced-dose craniospinal radiation therapy and adjuvant chemotherapy: a Children's Cancer Group study. *J Clin Oncol* 17:2127-2136.
- Packer RJ, Perilongo G, Johnson D, et al. 1992. Choroid plexus carcinoma of childhood. *Cancer* 69:580-585.
- Packer RJ, Seigel KR, Sutton LN, Litmann P, Bruce DA, Schuff L. 1985. Leptomeningeal dissemination of primary central nervous system tumors of childhood. *Ann Neurol* 18:217-221.

- Packer RJ, Siegel KR, Sutton LN, et al. 1988. Efficacy of adjuvant chemotherapy for patients with poor-risk medulloblastoma: a preliminary report. *Ann Neurol* 24:503-508.
- Packer RJ, Sutton LN, Elterman R, et al. 1994b. Outcome for children with medulloblastoma treated with radiation and cisplatin, CCNU, and vincristine chemotherapy. *J Neurosurg* 81:690-698.
- Petronio J, Edwards MS, Prados M, et al. 1991. Management of chiasmal and hypothalamic gliomas of infancy and childhood with chemotherapy. *J Neurosurg* 74:701-708.
- Pierre-Kahn A, Hirsch JF, Roux FX, Renier D, Sainte-Rose C. 1983. Intracranial ependymomas in childhood. Survival and results of 47 cases. *Childs Brain* 10:145-156.
- Pollack IF, Pang D, Albright AL. 1994. The longterm outcome in children with late-onset aqueductal stenosis resulting from benign intrinsic tectal tumors. *J Neurosurg* 80:20-25.
- Prados MD, Edwards MS, Chang SM, et al. 1999. Hyperfractionated craniospinal radiation therapy for primitive neuroectodermal tumors: results of a phase II study. *Int J Radiat Oncol Biol Phys* 43:279-285.
- Prados MD, Edwards MS, Rabbitt J, Lamborn K, Davis RL, Levin VA. 1997. Treatment of pediatric low-grade gliomas with a nitrosourea-based multiagent chemotherapy regimen. *J Neurooncol* 32:235-241.
- Prados MD, Wara WM, Edwards MS, Cogen PH. 1994. Hyperfractionated craniospinal radiation therapy for primitive neuroectodermal tumors: early results of a pilot study. *Int J Radiat Oncol Biol Phys* 28:431-438.
- Prados MD, Warnick RE, et al. 1995. Medulloblastoma in adults. *Int J Radiat Oncol Biol Phys* 32:1145-1152.
- Rawlings CE 3rd, Giangaspero F, Burger PC, Bullard DE. 1988. Ependymomas: a clinicopathologic study. *Surg Neurol* 29:271-281.
- Robertson PL, Zeltzer PM, Boyett JM, et al. 1998. Survival and prognostic factors following radiation therapy and chemotherapy for ependymomas in children: a report of the Children's Cancer Group. *J Neurosurg* 88:695-703.
- Rodriguez LA, Prados M, Fulton D, Edwards MS, Silver P, Levin V. 1988. Treatment of recurrent brain stem gliomas and other central nervous system tumors with 5-fluorouracil, CCNU, hydroxyurea, and 6-mercaptopurine. *Neurosurgery* 22:691-693.
- Rorke LB, Packer RJ, Biegel JA. 1996. Central nervous system atypical teratoid/rhabdoid tumors of infancy and childhood: definition of an entity. *J Neurosurg* 85:56-65.
- Rousseau P, Habrand JL, Sarrazin D, et al. 1994. Treatment of intracranial ependymomas of children: review of a 15-year experience. *Int J Radiat Oncol Biol Phys* 28:381-386.
- Rutka JT, Hoffman HJ, Becker LE, et al. 1990. Medulloblastoma: the clinical problem, molecular genetics, and mitogenic factors. *Dev Biol* 1:407.
- Salazar OM. 1981. Primary malignant cerebellar astrocytomas in children: a signal for postoperative craniospinal irradiation. *Int J Radiat Oncol Biol Phys* 7:1661-1665.
- Schold SC Jr, Brent TP, von Hofe E, et al. 1989. O6-alkylguanine-DNA alkyltransferase and sensitivity to procarbazine in human brain tumor xenografts. *J Neurosurg* 70:573-577.
- Sexauer CL, Khan A, Burger PC, et al. 1985. Cisplatin in recurrent pediatric brain tumors: a POG phase II study; a Pediatric Oncology Group Study. *Cancer* 56:1497-1501.
- Shaw EG, Evans RG, Schelthauer BW, Ilstrup DM, Earle JD. 1987. Postoperative radiotherapy of intracranial ependymoma in pediatric and adult patients. *Int J Radiat Oncol Biol Phys* 13:1457-1462.
- Silverman CL, Simpson JR. 1982. Cerebellar medulloblastoma: the importance of posterior fossa dose to survival and patterns of failure. *Int J Radiat Oncol Biol Phys* 8:1869-1876.
- Spoto R, Ertel IJ, Jenkins RD, et al. 1989. The effectiveness of chemotherapy for treatment of high grade astrocytomas in children: result of a randomized trial. A report from the Childrens Cancer Study Group. *J Neurooncol* 7:165-177.
- Stroink A, Hoffman HJ, Hendrick EB, Humphreys RP. 1986. Diagnosis and management of pediatric brain-stem gliomas. *J Neurosurg* 65:745-750.
- Sutton LN, Goldwein J, Perilongo G, et al. 1991. Prognostic factors in childhood ependymomas. *Pediatr Neurosurg* 16:57-65.
- Tait DM, Thornton-Jones H, Bloom HJG, Lemerle J, Morris-Jones P. 1990. Adjuvant chemotherapy for medulloblastoma: the first multi-centre control trial of the International Society of Paediatric Oncology (SIOP-I). *Eur J Cancer* 26:464-469.
- Thomas PR, Deutsch M, Mulhern R, et al. 1995. Reduced dose vs standard dose neuraxis irradiation in low stage medulloblastoma: the POG and CCG study. *Med Pediatr Oncol* 24:277.
- Tomita T, McLone DG. 1986. Medulloblastoma in childhood: results of radical resection and low-dose neuraxis radiation therapy. *J Neurosurg* 64:238-242.
- Tomita T, McLone DG, Das L, Brand WN. 1988a. Benign ependymomas of the posterior fossa in childhood. *Pediatr Neurosci* 14:277-285.
- Tomita T, McLone DG, Yasue M. 1988b. Cerebral primitive neuroectodermal tumors in childhood. *J Neurooncol* 6:233-243.
- van der Kogel AJ. 1991. Central nervous system radiation injury in small animal models. In: Gutin PH, Leibel SA, Sheline GE (eds), *Radiation Injury to the Nervous System*. New York: Raven Press, pp 91-111.
- Vanuytsel LJ, Bessell EM, Ashley SE, Bloom HJ, Brada M. 1992. Intracranial ependymoma: long-term results of a policy of surgery and radiotherapy. *Int J Radiat Oncol Biol Phys* 23:313-319.
- Vanuytsel L, Brada M. 1991. The role of prophylactic spinal irradiation in localized intracranial ependymoma. *Int J Radiat Oncol Biol Phys* 21:825-830.
- Wallner KE, Wara WM, Sheline GE, Davis RL. 1986. Intracranial ependymomas: results of treatment with partial or whole brain irradiation without spinal irradiation. *Int J Radiat Oncol Biol Phys* 12:1937-1941.
- Winston K, Gilles F, Leviton A, Fulchiero A. 1977. Cerebellar gliomas in children. *J Natl Cancer Inst* 58:833-838.
- Wolff JE, Sajedi M, Coppes MJ, et al. 1999. Radiation therapy and survival in choroid plexus carcinoma [letter]. *Lancet* 353:2126.
- Zeltzer PM, Boyett JM, Finlay JL, et al. 1999. Metastasis stage, adjuvant treatment and residual tumor are prognostic factors for medulloblastoma in children: conclusions from the Children's Cancer Group 921 randomized phase III study. *J Clin Oncol* 17:832-845.